

# The Role of Ultrasound in Venous Thoracic Outlet Syndrome: Lesson Based on a Case Report

Tiziana Vasile, Renato Farina\*, Pietro Valerio Foti, Antonio Basile

Department of Medical and Surgical Sciences and Advanced Technologies "GF Ingrassia", Radiodiagnostic and Radiotherapy Unit, Catania, Italy

## Abstract

Thoracic outlet syndrome is a rare neurovascular disease, usually caused by compression of subclavian vessels and/or brachial plexus by a cervical rib or hypertrophic scalene muscles. When the subclavian artery is compressed, it can cause perfusion deficiency with cyanosis and greater fatigue of the upper limb; if the subclavian vein is compressed, it can cause venous congestion with swelling and pain in the upper limb. When compression affects the brachial plexus, it can cause tingling or paresthesia of the upper limb. It can be mono or bilateral, congenital, or acquired. The diagnosis of vascular alterations is difficult due to the rarity, poor knowledge, and nonspecificity of symptoms. Ultrasound allows to localize and measure the vascular stenosis degree. Failure to diagnose can expose patients to serious health risks. We describe a rare case of venous compression caused by anterior scalene muscle hypertrophy.

**Keywords:** Anterior scalenus muscle, Doppler ultrasound, subclavian vein, thoracic outlet syndrome

## INTRODUCTION

Thoracic outlet syndrome (TOS) is a disease that is part of the vascular compression syndromes<sup>[1]</sup> and is due to compression of subclavian vessels or brachial plexus usually caused by a cervical rib<sup>[2]</sup> and/or by scalene muscles hypertrophy.<sup>[3]</sup> It was first described in the literature by Peet *et al.* in 1956.<sup>[4]</sup> Compressions are almost always asymptomatic and for this reason, they are not recognized, but for the syndrome to manifest the compressions must be significant for both the vascular and neurological forms. TOS treatment can be conservative or surgical. Physiotherapy and kinesitherapy are the most used and can achieve a reduction in vascular compressions due to scalene muscles hypertrophy.<sup>[5]</sup> The use of local pain relievers<sup>[6]</sup> can also reduce pain. Surgical treatment should only be reserved for severe cases and consists of scalenectomy and removal of first cervical rib, aimed at vascular decompression.

## CASE REPORT

We describe the case of a 40-year-old patient, previously operated on for breast cancer, who came to our imaging

department for suspected right axillary lymphadenopathy. For several months, the patient had been suffering from swelling in the right upper limb which appeared only upon awakening in the morning. She underwent an ultrasound (US) of axillary cavities, subclavian vessels, and scalene muscles bilaterally. A May Lab Nine ultrasound device (Esaote Biomedica, Genoa) 7–14 MHz linear probe was used. The US scans were performed with down and raised arms. The study of the subclavian vein was performed in the costoclavicular space. The US scans performed in the right and left axillary cavity with down arms did not show caliber alterations of the axillary artery and axillary vein, while right axillary vein dilatation occurred with raised arm [Figure 1a, b and Video 1]. The US also highlighted a significant reduction of peak speed velocity (PSV) in the right axillary vein with raised arm (2.8 cm/s), compared to PSV detected with a down arm (12.9 cm/s) [Figure 1c, d and Video 2], while no significant alterations were detected in the left axillary vein [Video 3]. The US performed in scalene muscles showed a greater thickness of the right anterior scalene muscle compared

**Address for correspondence:** Dr. Renato Farina,  
Department of Medical and Surgical Sciences and Advanced Technologies  
"GF Ingrassia", Radiodiagnostic and Radiotherapy Unit, Catania, Italy.  
E-mail: radfaro@hotmail.com

Received: 17-12-2021 Revised: 02-03-2022 Accepted: 29-03-2022 Available Online: 10-09-2022

Videos available on: <https://journals.lww.com/jmut>

### Access this article online

Quick Response Code:



Website:  
<https://journals.lww.com/jmut>

DOI:  
10.4103/jmu.jmu\_219\_21

This is an open access journal, and articles are distributed under the terms of the Creative Commons Attribution-NonCommercial-ShareAlike 4.0 License, which allows others to remix, tweak, and build upon the work non-commercially, as long as appropriate credit is given and the new creations are licensed under the identical terms.

For reprints contact: WKHLRPMedknow\_reprints@wolterskluwer.com

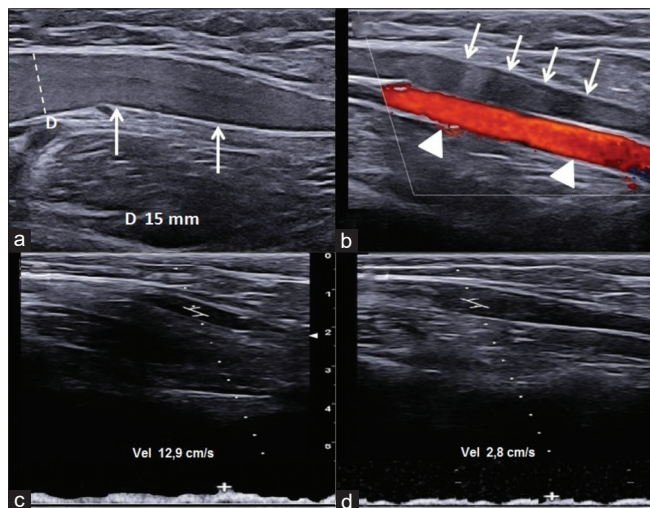
**How to cite this article:** Vasile T, Farina R, Foti PV, Basile A. The role of ultrasound in venous thoracic outlet syndrome: Lesson based on a case report. *J Med Ultrasound* 2023;31:150-3.

to the contralateral (14 mm vs. 11 mm), evident both at rest and with raised arms. The US of subclavian vessels showed a significant reduction in caliber (1, 5 mm) and PSV (5, 5 cm/s) in the right subclavian vein with raised arm [Figure 2a-d], with flow ratio (FR) (Poststenotic PSV/prestenotic PSV) of 6, 8. There were no morphological or flow alterations in the right subclavian vessels. The results are summarized in the Table 1. To exclude other causes of vascular compression, the patient underwent computed tomography (CT) examination performed with arms raised which confirmed right subclavian vein stenosis by the anterior scalene muscle [Figure 3]. The patient was advised to undergo conservative psychiatric and osteopathic therapy and periodic US follow-up of the right subclavian vein to monitor the evolution of the stenosis. 3 months after treatment, the patient reported a reduction of morning swelling of the right arm and US control showed a slight reduction in caliber (10 mm) and increase in PSV (8,6 cm/s) in the axillary vein and increase in caliber (2.5 mm) and in PSV (10.5 cm/s) in subclavian vein measured with arm raised.

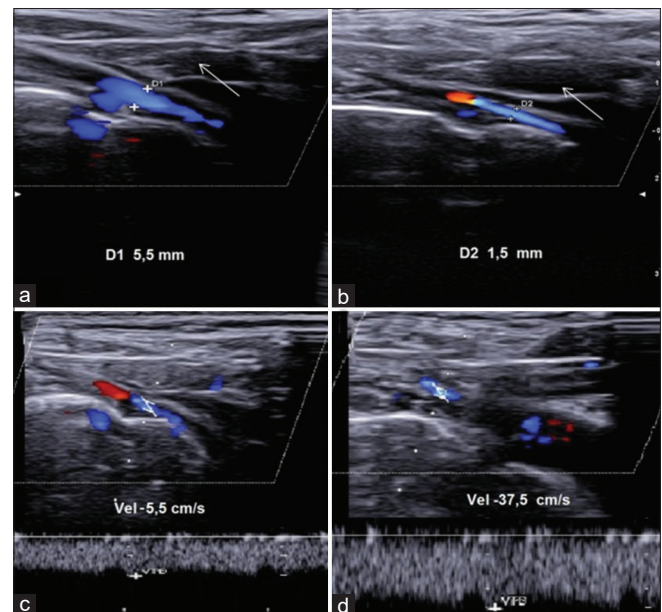
## DISCUSSION

Arterial TOS is rare, almost always caused by the cervical rib compressing the subclavian artery; in these patients, the compression is aggravated by the upper limb lifting causing also the loss of brachial pulse (Adson test).<sup>[7]</sup> The cervical rib is a not very rare anatomic variant that can be mono or bilateral and is generally asymptomatic.<sup>[8]</sup> Neurological TOS is caused by brachial plexus compression and, like arterial form, it is generally due to the cervical rib and can cause paresthesia and tingling in the upper limb. In venous TOS, the subclavian vein compression is due to one or more hypertrophic scalene muscles, more frequently the anterior scalene, and is more common in

athletes who strain shoulders and arms, it causes swelling, pain in the upper limb, and in more severe cases can cause thrombosis. The TOS diagnosis is based on symptoms, neurological tests, and instrumental investigations.<sup>[9]</sup> Standard X-ray can highlight the cervical rib, while the first level examination for the vascular alterations is US which can highlight the vascular compression and stenosis degree. CT or magnetic resonance imaging (MRI) allows for diagnosis and is primarily used to detect other causes of compression.<sup>[10]</sup> The US of the subclavian vein should be performed in the costoclavicular space which is the anatomical space formed inferiorly by the first rib, superiorly by the clavicle, and laterally by the anterior scalene muscle [Figure 4]; while the study of the subclavian artery (arterial TOS) is performed in the costoclavicular triangle which is the space formed anteriorly by the middle third of the clavicle, posteromedially by the first rib and posterolaterally by the upper profile of the scapula; in these patients, vascular compression is caused by the cervical rib and rarely by hypertrophic scalene muscles.<sup>[11]</sup> In our case, the discovery of flow congestion in the axillary vein occurred accidentally during a routine US follow-up of the axillary cavity which is performed with the arm raised and the return to normal flow with the lowering arm made us suspect the TOS. Subsequently, the comparative study with subclavian vessels and contralateral scalene muscles highlighted the right anterior scalene muscle hypertrophy, while CT excluded the presence of cervical ribs and other causes of vascular compression. The patient's symptoms were mild and appeared occasionally upon awakening as the patient was used to sleeping in a prone position, resting her head on her bent arm. In patients undergoing surgery for breast cancer, a frequent complication is the lymphedema of



**Figure 1:** Ultrasound of the right axillary cavity. (a) Ultrasound performed with raised arm shows axillary vein dilation (arrows) (15 mm in diameter) and color Doppler ultrasound (b) shows no signal (arrows) due to very slow flow. Axillary artery (arrow heads) (c) The flow measurement performed with lowered arm shows a regular Peak Speed Velocity (12.9 cm/s); that it is significantly reduced with raised arm (2.8 cm/s) (d)

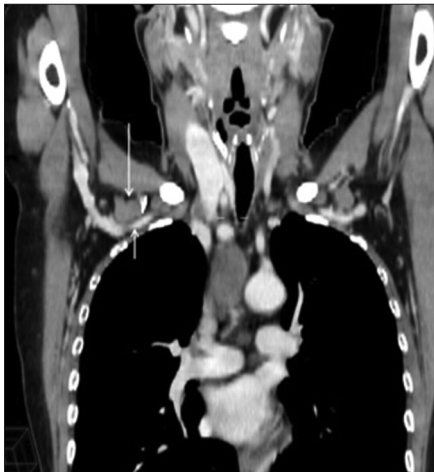

**Figure 2:** Ultrasound of the right subclavian vein. (a) The Ultrasound shows a regular diameter with a down arm. Anterior scalene muscle (arrow). (b) The diameter decreases with the arm raised. Anterior scalene muscle (arrow). (c) The flow measurement performed with raised arm shows a severe reduction in Peak Speed Velocity (5.5 cm/s) in prestenotic tract and an increase (37.5 cm/s) in poststenotic tract (d)

**Table 1: Summary of ultrasound result**

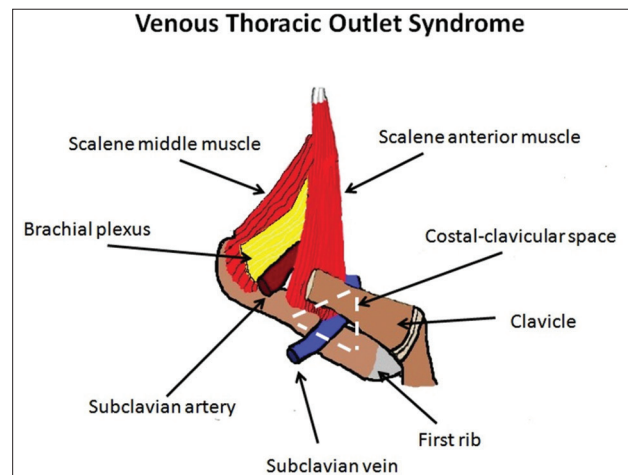
	PSV with raised arm (cm/s)	PSV with down arm (cm/s)	FR	Thickness with raised arm (mm)	Caliber with raised arm (mm)
Right subclavian vein	5	37.5	6.8		1.5
Left subclavian vein	40.9	46.7			8
Right axillary vein	2.8	12.9			15
Left axillary vein	32	34.5			6
Right anterior scalene muscle				14	
Right middle scalene muscle				10	
Right posterior scalene muscle				8	
Left anterior scalene muscle				11	
Left middle scalene muscle				9.5	
Left posterior scalene muscle				7.5	

PSV: Peak speed velocity, FR: Flow ratio



**Figure 3:** Computed tomography. In this view, according to a coronal plane, performed with raised arm the right subclavian vein compression (short arrow) by the anterior scalene muscle (long arrow) is highlighted

the upper limb due to lymphatic outflow congestion that causes arm swelling; but in our case, the arm swelling was only in the morning and had appeared a few months before the surgery. US in the diagnosis of TOS has some strengths compared to second-level methods such as CT and MRI, in fact, in addition, to easily locating vascular compressions, it allows scans to be performed with lowered and raised arms, while the CT and MRI examinations routinely, they are generally performed with lowered arms; moreover, it allows to obtain a flowmetric estimate of stenosis degree thanks to the FR measurement: A venous FR of 2.5 corresponds to stenosis of 50%.<sup>[12]</sup> Based on the stenosis degree, generally, the treatment to which the patient is to be subjected is decided. In this regard, in our opinion, asymptomatic patients with stenosis of <50% do not need treatment but only periodic US follow-up, while symptomatic patients with stenosis >70% should undergo physiokinesis and medical therapies with local anesthetics and ultrasonographic periodic for the stenosis follow-up. From the clinical history of our patient, no elements emerged that could justify the unilateral anterior scalene muscle hypertrophy, so it could be a rare case of congenital hypertrophy.



**Figure 4:** Schematic describing the main anatomical structures involved in venous Thoracic Outlet Syndrome. The costoclavicular space is the anatomical space involved in hypertrophic scalene syndrome and is formed inferiorly by the first rib, superiorly by the clavicle, and laterally by the anterior scalene muscle. In the costoclavicular space, subclavian vein compression is usually caused by anterior scalene muscle hypertrophy

## CONCLUSIONS

The diagnosis of vascular compressions is made difficult by their rarity, poor knowledge, and nonspecificity of symptoms. The diagnosis, as in this case, often occurs accidentally during routine US examinations as CT and MRI are generally performed with lowered arms while compression almost always occurs with raised arm; only a careful analysis of the clinical history can lead to suspicion of this syndrome as patients often overlook small signs that can be very important. More frequent and more thorough use of the US could significantly reduce false negatives. Failure to diagnose a patient with TOS can expose them to serious complications and risks to your health.

## Declaration of patient consent

The authors certify that they have obtained all appropriate patient consent forms. In the form, the patient has given her consent for her images and other clinical information to be reported in the journal. The patient understands that her name

and initials will not be published and due efforts will be made to conceal identity, but anonymity cannot be guaranteed.

### Financial support and sponsorship

Nil.

### Conflicts of interest

There are no conflicts of interest.

## REFERENCES

1. Jones MR, Prabhakar A, Viswanath O, Urits I, Green JB, Kendrick JB, *et al.* Thoracic outlet syndrome: A comprehensive review of pathophysiology, diagnosis, and treatment. *Pain Ther* 2019;8:5-18.
2. Jiang S, Shen H, Tan WQ, Lu H. Arterial thoracic outlet syndrome caused by cervical ribs-an unusual case report. *Medicine (Baltimore)* 2019;98:e14778.
3. Baltopoulos P, Tsintzos C, Prionas G, Tsironi M. Exercise-induced scalenus syndrome. *Am J Sports Med* 2008;36:369-74.
4. Peet RM, Henriksen JD, Anderson TP, Martin GM. Thoracic-outlet syndrome: Evaluation of a therapeutic exercise program. *Proc Staff Meet Mayo Clin* 1956;31:281-7.
5. Hixson KM, Horris HB, McLeod TC, Bacon CE. The diagnostic accuracy of clinical diagnostic tests for thoracic outlet syndrome. *J Sport Rehabil* 2017;26:459-65.
6. Bortolani E, Miani S, D'Armini A, Gallo E, Morbidelli A. Role of anterior scalene muscle hypertrophy in thoracic outlet syndrome. *Minerva Chir* 1989;44:1305-9.
7. Farina R, Foti PV, Conti A, Iannace FA, Pennisi I, Fanzone L, *et al.* The role of ultrasound imaging in vascular compression syndromes. *Ultrasound J* 2021;13:4.
8. Kwee RM, Borghans RA, Bruls RJ, Fasen BA, Kuburic D. Diagnostic performance of diffusion-weighted MR neurography as an adjunct to conventional MRI for the assessment of brachial plexus pathology. *Eur Radiol* 2022;32:2791-7.
9. Vanti C, Natalini L, Romeo A, Tosarelli D, Pillastrini P. Conservative treatment of thoracic outlet syndrome. A review of the literature. *Eura Medicophys* 2007;43:55-70.
10. Weaver ML, Hicks CW, Fritz J, Black JH 3<sup>rd</sup>, Lum YW. Local anesthetic block of the anterior scalene muscle increases muscle height in patients with neurogenic thoracic outlet syndrome. *Ann Vasc Surg* 2019;59:28-35.
11. Farina R, Foti PV, Iannace FA, Conti A, Ferlito A, Conti A, *et al.* Thoracic outlet syndrome: A rare case with bilateral cervical ribs and bilateral anterior scalene hypertrophy. *J Ultrasound* 2021;24:331-6.
12. Farina R, Foti PV, Pennisi I, Conti A, Meli GA, Vasile T, *et al.* Stylo-Jugular venous compression syndrome: Lessons based on a case report. *Am J Case Rep* 2021;22:e932035.